

Endovascular Coiling of Cerebral Aneurysms

What is an Aneurysm?

An aneurysm can be thought of as a bubble arising from the wall of an artery, in an area of weakness or thinning of the wall, much like a bubble produced by an area of weakness in the old-style inner tubes for bicycle or automobile tires. Intracranial aneurysms constitute a significant public health problem in the United States. Rupture of cerebral aneurysms typically results in subarachnoid hemorrhage (bleeding within the fluid space surrounding the brain) and affects 10-30/100,000 patients/year (about 30,000 patients in the United States per year). As many as 10% of these patients die before reaching the hospital. Of those who do reach the hospital, the greatest risk to life is aneurysm re-bleeding, although progressive narrowing of arteries which occurs in response to the presence of blood around the brain ("cerebral vasospasm") has a significant contribution to overall morbidity (impairment) and mortality (death). Considering that as many as 50% of subarachnoid hemorrhage patients eventually die as a result of their hemorrhage, and an additional 25% suffer permanent neurological injury, any cerebral aneurysm deserves a thorough evaluation for potential treatment.

The primary goal of treatment of cerebral aneurysms is to prevent future rupture. What can we tell patients about their risk of future rupture? Until recently, the best available data suggested that previously unruptured aneurysms carry a risk of hemorrhage of about 1-2 %/year. However, a recent study published in the New England Journal of Medicine suggests a much lower rate of hemorrhage of unruptured aneurysms less than 1cm in size (less than ½ inch). Although there has been some criticism of the methods used in this

study, it is probably true that the risk rupture of most aneurysms less than 1cm is significantly less than was previously thought. If subdivided by size, the risk of rupture is probably slightly lower for small aneurysms (< 1cm) and slightly higher for large aneurysms (1cm - 2.5cm). The presence of multiple aneurysms, or a family history of subarachnoid hemorrhage, also appear to raise the risk of rupture. Once an aneurysm has ruptured, the chance of re-hemorrhage dramatically increases. Of those patients who survive an initial subarachnoid hemorrhage, if the aneurysm is left untreated, approximately 20% will have recurrent bleeding in the first 2 weeks, and 35% over the first month. After the first 30 days the risk of rebleeding falls back to about 1-2 % per year.

Surgical Treatment of Aneurysms

Surgical clipping has been the mainstay of treatment of both ruptured and unruptured cerebral aneurysms. In this approach, the affected artery must be exposed, and the aneurysm visualized directly. The surgeon can then carefully apply a metal clip to the base of the aneurysm thereby blocking blood flow into the aneurysm. Once the aneurysm is eliminated from the flow of blood the risk of hemorrhage is eliminated, for the vast majority of patients. The advent of microneurosurgical techniques and advancements in cerebrovascular surgery (temporary clipping, neuroprotection, etc.) have extended the applicability of aneurysm surgery and improved surgical outcomes. In spite of these advancements, there remain aneurysms which are difficult to clip even in the best of hands.

Aneurysm Coiling (“endovascular” treatment)

In 1991, Guglielmi detachable coil (GDC) treatment was introduced as an alternative method for treating selected aneurysms. The GDC system consists of a very soft and flexible microcoiled platinum wire with intrinsic helical memory that is attached to a very fine delivery wire. The coil is attached to the wire by a special soldered joint and can be "detached" once in the aneurysm by electrolysis (attachment site is dissolved by a tiny electrical current). GDC "embolization" (or plugging) of an aneurysm involves delivery of these platinum coils into the lumen of the aneurysm by way of a microcatheter (tiny tubing, about the size of household string) placed into the aneurysm from within the artery, from access at the groin. The goal of the treatment is to prevent the flow of blood into the aneurysm sack by filling the aneurysm with coils and thrombus (clot). It has been shown that this approach leads to organization of the thrombus in the aneurysm. With further healing a membrane forms across the neck of the aneurysm. In some (but not all) cases this membrane is complete, excluding of

the aneurysm from the flow of blood. Even without complete exclusion of the aneurysm from circulation by a complete membrane, the scarring produced by the coils appears to stabilize the aneurysm, markedly decreasing the incidence of aneurysm re-rupture.

Theoretically, there are several advantages of GDC over surgery. These procedures are performed under general anesthesia in the neuroangiography suite utilizing the standard transfemoral (from the groin) approaches used in diagnostic angiography. Open surgery, with craniotomy (surgical creation of an opening in the skull) and scalp incisions are avoided. In some cases, the treatment can be combined with the initial diagnostic cerebral angiogram thereby reducing the period of risk of re-rupture. Because the approach is transarterial, multiple aneurysms can be treated during a single procedure, and GDC treatment can be combined with treatment of related conditions such as vasospasm (intra-arterial infusion of papaverine or microballoon angioplasty). Since there is no scarring of the route of approach to the aneurysm as there is in the case of surgery, staged or multiple procedures can be performed without added difficulty. Finally, since the approach is "endovascular", the issues which make any particular location relatively straightforward or more difficult are entirely different. Therefore, some locations which are relatively difficult for surgery (such as the basilar tip) can be relatively straightforward for GDC treatment. Of course, the opposite can be true of other sites (e.g. middle cerebral artery aneurysms).

Despite these potential advantages, surgery may be considered to be the primary treatment modality for some aneurysms. Surgical clipping has been successfully applied to intracranial aneurysms for many years, and the durability of the treatment has been proven. Surgery also minimizes the need for post procedure angiographic studies, which are required for any patient treated with GDC. Surgery can also provide controlled access to areas of difficult anatomy and can allow for arterial reconstruction for aneurysms with complex shapes and wide necks in which the GDC technique cannot be readily applied. Giant aneurysms are also less likely to have a completely successful outcome after GDC embolization. Such aneurysms have a significant likelihood of coil compaction into the aneurysm, causing a recurrence of the aneurysm lumen. Aneurysms that project along the direction of blood flow in the parent artery (e.g., superiorly directed basilar tip) are also at increased risk for coil compaction into the aneurysm. Certainly, the best results following GDC coiling are achieved with small aneurysms (less than 10-15mm) which also have small necks.

Since its inception the technique of GDC embolization has evolved as a result of both clinical experience and the introduction of improvements in the technology. We are now better at selecting aneurysms appropriate for treatment, and we have more advanced equipment and imaging than was originally available, even compared with two-three years ago. Technological advances in GDC technology which have improved this method of treatment over the last several years, include an increase in the number of coil sizes, multi-dimensional coils which allow safer initial coil placement, and the introduction of much softer coils. In more complex cases, the use of soft, microballoons and or stents have recently been used to better control the neck of the aneurysm during coiling. The manufacturing process which forms the attachment of the platinum coil to the stainless steel introducing wire has been improved, so that the detachment zone dissolves much quicker, dramatically reducing the time needed to detach each coil. Another significant technical refinement has been in the area of microcatheters. We now have "braided" (reinforced), hydrophilically coated (become slippery when wet) microcatheters, which allow improved access to many aneurysms, thereby increasing our chances of obtaining complete aneurysm obliteration.

Important imaging advancements occurring over the last few years include the use of high resolution, biplane angiography with 3-dimensional angiography (computer produces 3 dimensional images from an angiogram), and advancements in 3-dimensional computer reconstructions produced from CT angiography ("CAT" scans), as well as MR angiography. Patient's being considered for aneurysm treatment may undergo any or all of these various new images tests.

When should GDC Treatment be considered?

The use of GDC coils is most strongly considered in any patient in whom surgery may carry an increased risk. These typically include patients with other serious medical conditions, patients with a higher degree of initial neurological impairment following rupture of an aneurysm (Hunt & Hess Grades III-IV), or with increased intracranial pressure following aneurysm rupture. Aneurysms in which surgical exposure carries an unacceptable risk, or those, which may not easily hold a surgical clip such as calcified atherosclerotic aneurysms, may also be good candidates for GDC treatment. In such cases GDC becomes the primary treatment option. GDC may also be offered to older patients, and in patients who wish to have treatment but do not want to have a craniotomy (open neurosurgical procedure).

Risks of aneurysm coiling

In some cases, the coiling procedure is unsuccessful, and surgical treatment is recommended.

Although it is not at all common, death or severe, disabling stroke can result from attempts to coil a ruptured, or unruptured aneurysm.

Risks of aneurysm coiling include risk of developing stroke or stroke-like symptoms. These are a result of clot forming during the coiling procedure (most common complication, but seen in less than 10% of cases). To minimize the risk of this complication, all patients undergoing coiling procedures are given anti-clotting medicines during the procedure. There is also risk of rupture of the aneurysm (very uncommon), or injury to other vessels. For various reasons (ask your treating physician for more detail), treatment of ruptured aneurysms should be considered somewhat higher risk than an unruptured aneurysm, for either coiling or surgical treatment. Complications can also occur at the site of arterial access at the groin, including bleeding, infection or development of a "pseudoaneurysm" (a bubble arising from the site of puncture), which may require injection of clotting medicine or a small surgery to close the site puncture with a stitch.

Post coiling patient management

Management of patients after successful coiling of an aneurysm will depend on whether the aneurysm was ruptured or unruptured, and whether or not there are any special concerns regarding the results of the coiling procedure (loops of coil projecting through the neck of the aneurysm, residual aneurysm neck, suspected penetration of coils through the aneurysm, etc.). In the large majority of patients undergoing coiling of unruptured aneurysm, the patient remains completely asymptomatic, and is discharged the following day. If the patient develops stroke-like symptoms, the hospitalization is more prolonged. In cases of ruptured aneurysms treated with GDC coils, the hospital course is determined by severity of symptoms related to the initial aneurysm rupture, and the degree of cerebral vasospasm that develops as a result of the bleeding around the arteries at the base of the brain. Generally, patients are observed in an intensive care unit for several days and given supportive care (intravenous fluids and other medical therapy), then transferred to regular hospital bed when stable. The overall hospitalization may be as short as 5-7 days, but can be much longer in patients with more severe symptoms.

Required follow-up

All patients undergoing aneurysm coiling require further imaging follow-up, to insure that the coils remain in a stable configuration and that the aneurysm does not show continued growth. Means of assessing coil and aneurysm stability include repeat cerebral angiograms, in some cases with the use of 3D rotational angiography, and plain x-ray films of the skull, which assess the configuration of the coils. Although the aneurysm itself is not visible on the plain x-ray films of the skull, in most cases of aneurysm regrowth, the coils change shape, as they "relax" into the enlarging aneurysm. Coil "compaction" refers to further, spontaneous packing of the coils into the aneurysm, which can occur in the days or weeks after the coiling procedure, exposing some of the aneurysm "neck" (entrance into the aneurysm). In some cases, significant coil compaction, or continued growth of the aneurysm itself, may lead to the recommendation for a second (or even third) GDC coiling procedure, to fully pack the aneurysm. Alternatively, recommendation may be made to proceed to conventional surgical clipping of the aneurysm.

At Virginia Mason Medical Center, our current policy for follow-up imaging, in most cases is as follows:

For non-ruptured aneurysm, plain x-ray films of the skull are obtained after the coiling procedure, and again at three months. A conventional angiogram is then obtained at approximately six months, one year, and finally two years after the procedure. In most cases, if the aneurysm appears stable after two years, no further follow-up is required, or follow-up can be limited to plain films of the skull for an additional year or two.

For ruptured aneurysms, the follow-up includes plain x-ray films of the skull before discharge from the hospital, and again on a follow-up clinic visit at 4-6 weeks, with follow-up conventional angiograms (often with 3D rotational angiography), performed at three months, six months, and finally two years after the procedure. As with unruptured aneurysms, if the aneurysm appears stable after two years, no further follow-up is required, or follow-up can be limited to plain films of the skull for an additional year or two. In some cases, some of these follow-up angiograms, and/or plain film studies, will be obtained in institutions other than the downtown Virginia Mason hospital, for the convenience of the patient and or the referring physician.

Keeping track of follow-up appointments

Although the treating physicians will keep track of the patient's follow-up schedule, it is also recommended that the patient (or patient's family) also keep the follow-up dates on their calendars, to avoid missing a recommended follow-up study, or some other misunderstanding.

Post coiling Medications

Most patients will also be placed on aspirin for three-six months following the coiling procedure, to reduce even further the small chance of clot forming on the surface of the coils, producing stroke-like symptoms. The patient may also be placed on other medications following coiling of ruptured or unruptured aneurysm.

Who to call with Questions or Concerns:

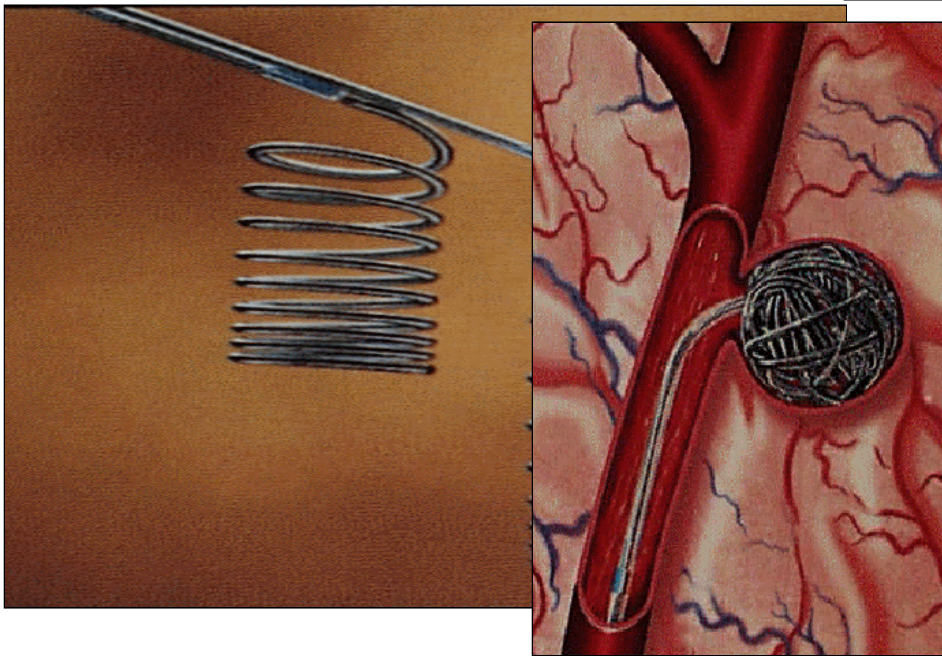
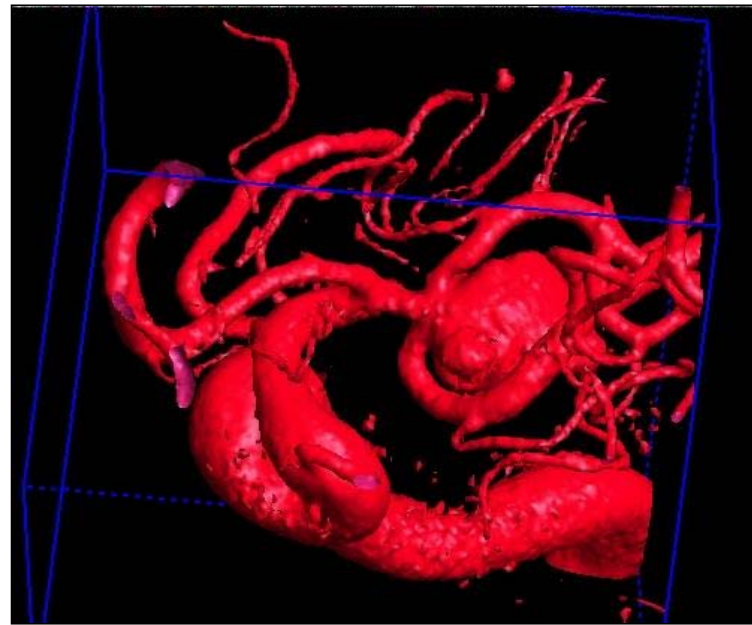
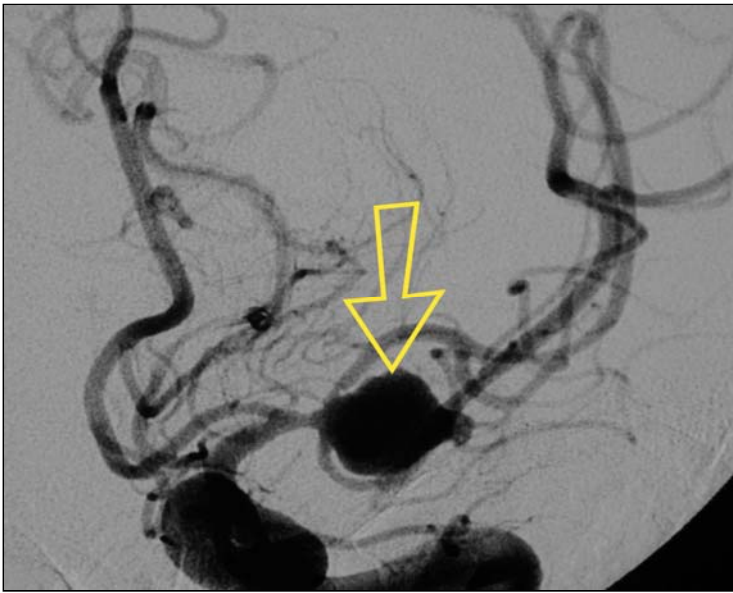
Virginia Mason Interventional Radiology Clinic (206) 341-0495

Virginia Mason Radiology: (206) 223-6851

Virginia Mason Emergency Room: (206) 583-6433

Voice mail for Dr. David H. Robinson, MD: (206) 341-0935

Your referring physician's office: Dr. _____ @



Illustrations of Detachable Coil Treatment of Cerebral Aneurysms

Above: left middle cerebral artery aneurysm angiogram, including 3-D angio.

Left: Two GDC coils (magnified view) & a diagram of a coil being placed into an aneurysm through a small tube (microcatheter) positioned within the aneurysm

Below: Post treatment angiogram of the left middle cerebral aneurysm shown above.

