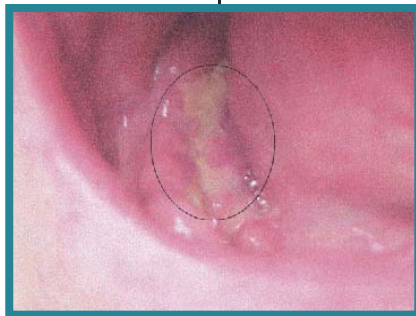


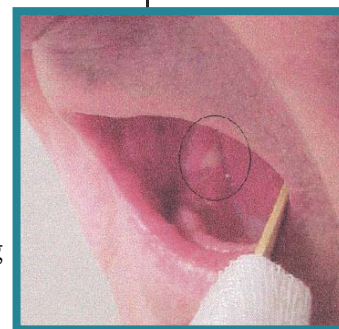
Hyperbaric Oxygen Treatment for Osteoradionecrosis

Each year 1.2 million new cases of invasive cancer are diagnosed in the United States. Of these, approximately one-half will receive radiation therapy, and approximately one-half of this group will become long-term survivors. Unfortunately, of these long-term survivors, about five percent will develop complications related to radiation treatment usually following a delay or latent period. Radiation therapy may produce an obliterative endarteritis in the adjacent normal tissue that progressively worsens over time producing a bone and soft tissue envelope in the target field that is hypovascular, hypocellular, and hypoxic (ref 1). As shown in Figure 1, accidental trauma, intentional surgical intervention, or infection may produce injury in tissue that is unable to respond with an effective healing response.

Osteoradionecrosis of the mandible following radiation therapy is defined as the presence of exposed bone, present for 6 months or longer without healing, and is the classic example of late post radiation injury and the value of hyperbaric oxygen treatment. Hyperbaric oxygen treatment has been shown to be beneficial in both prevention of progression to



frank necrosis in patients at risk with existing radiation tissue injury and in the treatment of those in whom bone and soft tissue necrosis has already occurred (ref 2). Hyperbaric oxygen treatment has been shown to stimulate angiogenesis within previously irradiated tissue restoring measured tissue oxygen levels to about 80 percent of non-irradiated tissue values restoring vascular and cellular density, supporting osteoclast resorption of necrotic bone.



aggressive protocol of preparative hyperbaric oxygen treatment, surgical debridement, and mandibular reconstruction summarized in Table 1.

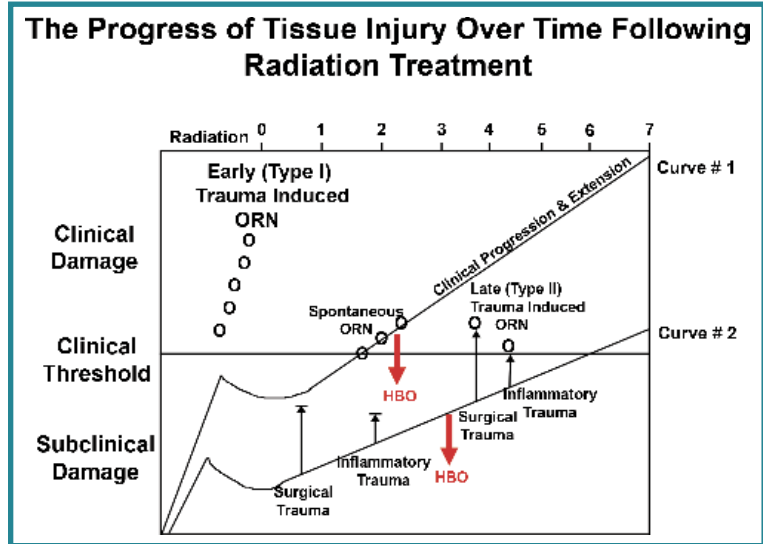


Figure 1. The Progress of Tissue Injury Over Time Following Radiation Treatment

Radiation tissue injury occurs in two phases: an acute phase (type I) that occurs during or shortly after radiation treatment, and a late or progressive phase (type II) that typically occurs several years following radiation treatment. Surgical trauma, local inflammation, or infection can move the curve to the clinical threshold of frank radionecrosis. HBO can move the injury curve down below the clinical threshold.

Pressure Points

Table 1. The Marx Protocol for Established Osteoradionecrosis

Stage I: All patients are initially placed in Stage I except those with advanced disease (14% resolve at Stage I ref 3)

- If there is improvement after 30 HBO treatments, they continue to complete a total of 40 treatments in the protocol
- If there is residual exposed necrotic bone after 30 treatments, they advance to Stage II

Stage II: All patients who have not responded to the initial 30 treatments with significant improvement or resolution (18% resolve at Stage II ref 3)

- All have transoral sequestrectomy followed by 10 more HBO treatments for a total of 40 treatments in the protocol
- Non-responders advance to Stage III

Stage III: Patients with pathologic fracture, oral/cutaneous fistula, or radiographic evidence of full thickness bone loss usually go to mandibular resection and reconstruction (68% resolve at Stage III ref 3)

Prevention of Osteoradionecrosis

Hyperbaric oxygen treatment has also been shown to be effective in preventing or reducing the severity of complications in patients who require removal of teeth or elective reconstructive surgery within a previously irradiated field. Marx (ref 4) demonstrated when patients received 20 pre-extraction hyperbaric oxygen treatments followed by 10 post-extraction treatments then incidence of developing osteoradionecrosis following tooth removal fell from 29.9 percent to 5.4 percent.

In patients having elective mandibular reconstruction, Marx and Johnson (ref 3) have fewer wound dehiscences (11 vs 48%), wound infections (6 vs 24%) and fewer instances of delayed healing (11 vs 56%) (ref 4). The hyperbaric oxygen treatment protocol used is once daily hyperbaric oxygen treatment administered at 2.4 ATA for 90 minutes of 100 percent oxygen breathing.

Complications

The most common complication of hyperbaric oxygen treatment is middle ear barotraumas which may occur slightly more frequently in patients who previously received head and neck radiation. Central nervous system oxygen toxicity can also occur. For this reason all patients referred for hyperbaric oxygen treatment for radiation tissue injury must be evaluated and managed by a physician specifically trained in hyperbaric medicine. There is no increased incidence of recurrence of oral cancer or increased rate of tumor growth.

Recommendation

Hyperbaric oxygen treatment has been shown in a recent evidence based review (ref 5) to provide significant benefit in treating established and preventing new osteoradionecrosis in patients at risk. Patients with established osteoradionecrosis or who have had previous head and neck radiation treatment and who are scheduled for elective dental extraction or oral maxillary surgical procedures should be referred for evaluation for hyperbaric oxygen treatment (ref 6).

References

- (ref 1) Marx RE. Osteoradionecrosis: A new concept of its pathophysiology. *J Oral Maxillofac Surg* 1983; 41:283-288.
- (ref 2) Marx RE. Part II: A new concept in the treatment of Osteoradionecrosis. *J Oral Maxillofac Surg* 1983; 41:351-357.
- (ref 3) Johnson RP, Marx RE, Buckley SB. Hyperbaric oxygen in oral and maxillofacial surgery. In: *Controversies in Oral and Maxillofacial Surgery*. P Worthington and JR Evans (eds). Philadelphia, WB Saunders Co., 1994, pp107-126.
- (ref 4) Marx RE, Johnson RP, Line SN. Prevention of Osteoradionecrosis: A randomized prospective clinical trial of hyperbaric oxygen versus penicillin. *J Am Den Assoc* 1985; 11:49-54.
- (ref 5) Feldmeier JJ, Hampson NB. A systematic review of the literature reporting the application of hyperbaric oxygen prevention and treatment of delayed radiation injuries: An evidence based approach. *UHM* 2002; 29(1):4-30.
- (ref 6) National Institutes of Health Consensus Development Conference on Oral Complications of Cancer Therapies: Diagnosis, Prevention, and Treatment in NCI Monograph Number 9, 1990

† CATHOLIC HEALTH
INITIATIVES

Franciscan Health System
St. Joseph Medical Center

Hyperbaric Medicine Service

1717 South "J" Street • Tacoma, WA 98401

Ph: (253) 426-6630 • Fax: (253) 426-6545

www.fhshealth.org/location/sjmc.asp

Pressure Points

A Publication of Praxis Clinical Services
Robert A Warriner, III, M.D., FACA, FCCP
Chief Medical Officer

17772 E. 17th Street, Suite 205
Tustin, CA 92780
888-345-3300

www.PraxisUSA.com